

# Case Report: Rare Presentation of Aspergillosis of Breast Masquerading as Breast Carcinoma

Sachin S Kadam <sup>1\*</sup>, Tejaswini Kadam<sup>2</sup>

<sup>1</sup> Dept of Surgical Oncology, Vedant Cancer & Multispecialty Hospital, Mumbai, India.

<sup>2</sup> Dept of Ophthalmology, Conwest & Jain Superspecialty Eye Hospital, Mumbai, India.

\*Correspondence Author: Sachin S Kadam, Dept. of Surgical Oncology, Vedant Cancer & Multispecialty Hospital, Mumbai, India

Received Date: February 06, 2023 | Accepted Date: February 21, 2023 | Published Date: March 02, 2023

**Citation:** Sachin S Kadam, Tejaswini Kadam. (2023) Case Report: Rare Presentation of Aspergillosis of Breast Masquerading as Breast Carcinoma. *Carcinogenesis and Chemotherapy*.2(2); DOI:10.31579/2835-9216/006

**Copyright:** © 2023 Sachin S Kadam, this is an open-access article distributed under the terms of the Creative Commons Attribution License, which permits unrestricted use, distribution, and reproduction in any medium, provided the original author and source are credited.

## Abstract

We are reporting a case of 39 year old lady who presented with large lump in the breast mimicking as breast carcinoma and after surgical excision diagnosed as breast aspergilloma. Aspergillus fungal infection of the breast is a very rarely encountered phenomenon. In the literature, only countable cases has been reported which were also encountered in immunosuppressed host. Breast aspergilloma in an immunocompetent patient is an extremely rare situation. The source of breast fungal infections are considered via contamination of implants during manufacture, airborne dissemination, hematogenous dissemination or nosocomial spread from the operating room environment. The most common presumed source in most of the patients is considered as airborne infection during a surgical procedure. A team of surgeon, pathologist and microbiologist are necessary for the diagnosis and management of patients with aspergillus infection of the breast. Breast aspergilloma patients should be addressed with early and aggressive surgical and medical treatment.

**Keywords:** aspergillosis; breast; immunocompetent; carcinoma; surgical excision

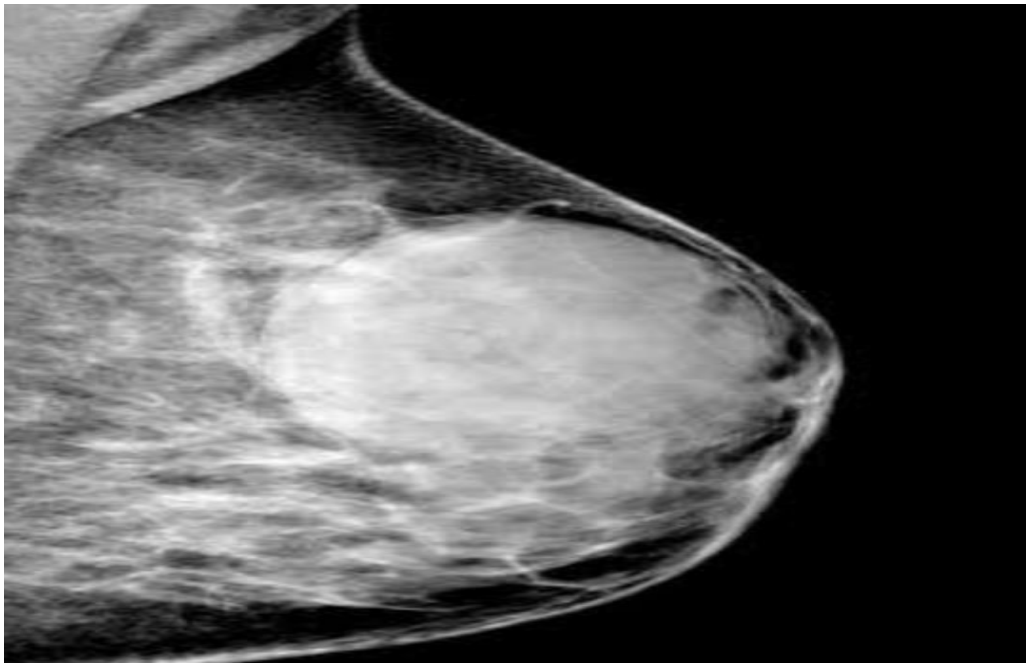
## Introduction

Aspergillus is a ubiquitous saprophytic fungus. Near about 200 species has been detected which may cause pulmonary aspergilloma, allergic bronchopulmonary aspergillosis, endocarditis, paranasal sinus infection and implant infections [1]. Aspergillus fungal infection is usually encountered in immunocompromised individuals with very rare occurrence in immunocompetent host [2]. Species belonging to this group are *A. fumigatus*, *A. flavus*, *A. Niger*, *A. terreus* [3]. Fungal infections of the breast have been reported in association with prosthetic breast implants [4]. The source of breast fungal infections are considered via contamination of implants during manufacture, airborne dissemination, hematogenous dissemination or nosocomial spread from the operating room environment or instruments during surgery [5]. The most common presumed source in most of the patients is considered as airborne infection during a surgical procedure [6]. We are reporting a case of 39 year old lady who presented

with large lump in the breast mimicking as breast carcinoma and after surgical excision diagnosed as breast aspergilloma.

## Case Report:

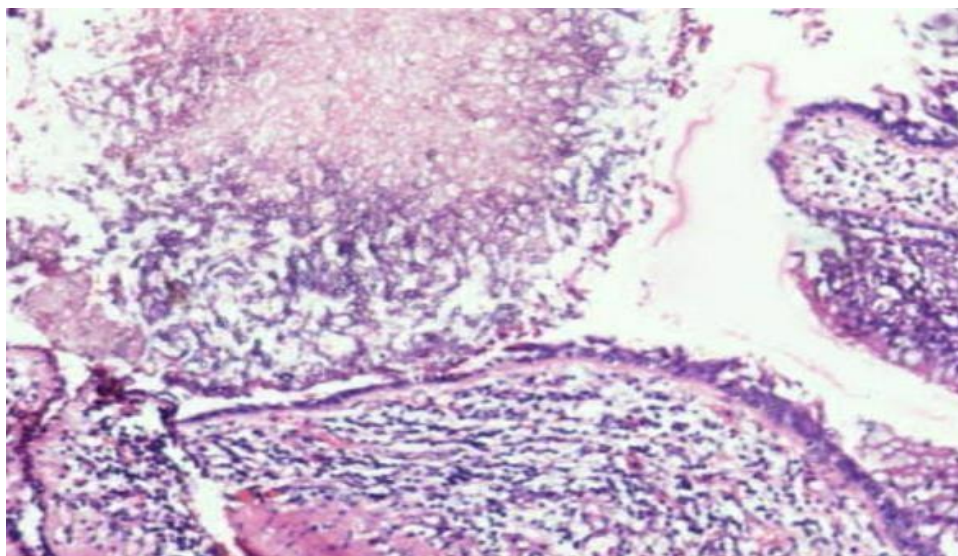
A 39 year old lady with Eastern Cooperative Oncology Group Performance Status 1 (ECOG PS – 1) with no comorbidity presented with a large right breast lump for the last 20 days. There was no positive surgical, family, past or medical history. Obstetric and menstrual history was normal. Patient had noticed right breast lump while bathing around 20 days back. She consulted a local physician who advised her to undergo mammogram and Fine Needle Aspiration Cytology (FNAC). Mammogram was suggestive of large lobulated lesion in the right breast measuring 10x 7.3cm suspicious of breast neoplastic lesion with BIRADS IV –C grading with one sub-centimetre right axillary lymph node of size 1.5x1cm with fatty hilum [Figure.1].



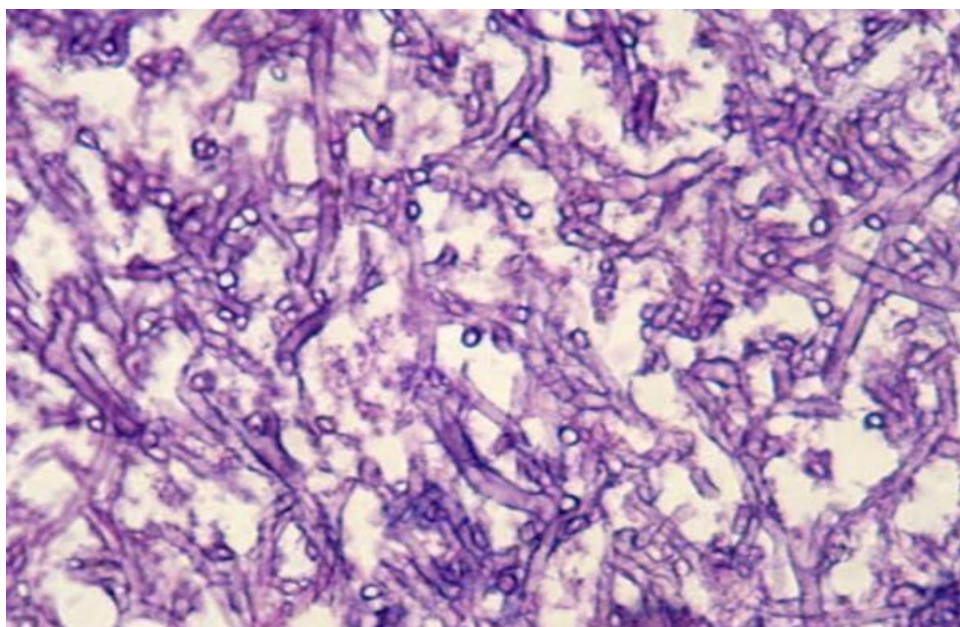
**Figure. 1: mammography image of the breast lesion**

FNAC was inconclusive. She was referred to our clinic with these reports. On clinical examination, a single, hard, well defined lump was palpable in the right breast in central quadrant with normal nipple-areola complex. A single, mobile lymph node of size 2x1cm was palpable in the right axilla. Left breast and axilla were normal. Rest of the systemic examination was unremarkable. Clinically, the impression of findings was in favor of breast carcinoma. Hence, we advised her to undergo core needle biopsy and it was suggestive of a purulent aspirate with no evidence of atypical or malignancy. Case was discussed in our institutional multidisciplinary tumor board. Our board decided to plan for wide excision of the breast lesion with frozen section control after metastatic work up. Thus, we advised her chest x ray and ultrasound of abdomen with pelvis. Metastatic work up was normal. As

per board's decision, patient underwent wide excision of the breast lesion with adequate margins and specimen was sent for frozen section control. Frozen reported it as pus containing cystic to firm lesion with no evidence of malignancy. Hence, we abandoned the further procedure. Patient was started on oral diet 6 hours post extubation and she was discharged in the evening on the same day. Final histopathology report described presence of multiple whitish, cystic to firm pus containing lesions with presence of dense inflammatory infiltrate with scanty granulomatous inflammation and multinucleate giant cells with no evidence of malignancy. Gene expert and culture was negative for mycobacterium tuberculosis and positive for aspergillus flavum [Figure 2, 3].



**Figure. 2: Aspergillus fungal hyphae (Low magnification)**



**Figure. 3: Aspergillus fungal hyphae (High magnification)**

Wound dehiscence occurred on 6th postoperative day. It was managed conservatively with alternate day dressing and after 1 month of dressing wound healed by secondary intention. Palpable axillary lymph node was disappeared after one month. She was in periodic follow up with us according to our institutional follow up protocol and after one year of completion of her treatment, she is disease free.

### Discussion:

Aspergillus is an opportunistic fungus. The growth and invasion depends on the biological features of the fungus and the immune status of the host [2]. They produce conidia which defines and characterizes its infectious life cycle [7]. These conidia are responsible for spread of infection onwards. They have a special characteristic of dispersion into the air when they come in contact with compassionate environment like lungs of an immunocompromised host where they germinate and become hyphae. The hyphae is the invasive form of Aspergillus fungus. The hyphal growth has the tendency to invade blood vessels which results in infarction, hemorrhagic necrosis and dissemination to other organ [8]. The most commonly affected organs are the lungs and paranasal sinuses followed by with less frequencies in the skin, heart, kidney, gastrointestinal tract and brain. They manifest with extra-pulmonary signs and symptoms [9]. However, in the index case, there was absence of such positive history.

Aspergillus fungal infection is found in over 90% patients who are immunosuppressed due to bone marrow transplantation, solid organ transplantation, cytotoxic chemotherapy, corticosteroid therapy and AIDS [10]. Aspergillus infection is diagnosed by biopsy with demonstration of septate, acute branching hyphae in the breast tissue [11]. Histopathology helps in detecting aspergillus fungal hyphae in necrotic material with distorted giant cells and final result will be possible after positive fungal culture [11]. The diagnosis is only possible with fungal culture. In immunocompetent patient, it's difficult to detect aspergillus infection in the breast as radiology will be non-specific. In the index case, only after gene expert and fungal culture, we were able to diagnose aspergillus infection. It's treating clinician and pathologist's thinking and implementation which directs and helps in detecting fungal infection.

The treatment of breast aspergilloma needs a combination of surgical and medical treatment to avoid unnecessary complications. The surgical procedure is complete excision of the breast aspergilloma and recommended medical treatment for cutaneous aspergillosis is voriconazole, itraconazole, and amphotericin B. Voriconazole has been shown to be statistically superior to amphotericin B [12]. We did complete surgical excision and she had been

given voriconazole in the postoperative period however, wound dehiscence occurred on 6th postoperative day which was managed conservatively with alternate day dressing. Aspergillus fungal infection of the breast is one of the causative factor for non-healing breast wound [13].

Surgeon, pathologist, microbiologist should have an idea of organism specific diagnosis when there is aspergillus infection in the breast and especially surgeon should have a high index of suspicion [14]. The aim of presenting this case is to project the fungal infections as one of the rare cause of breast aspergilloma other than mycobacterium [15]. Until now, less than 10 case of breast aspergilloma has been reported in the literature.

### Conclusion:

Aspergillus fungal infection can involve breast even in immunocompetent host, hence slow growing and long standing breast lump should be investigated with high index of suspicion of aspergillus infection. Breast aspergilloma patients should receive early and aggressive medical and surgical treatment.

### References:

1. Pasqualotto AC, Denning DW. Post-operative aspergillosis. *Clin Microbiol Infect* 2006 Nov; 12(11):1060–1076.
2. Garcia-Vidal C, Viasus D, Carratalà J. Pathogenesis of invasive fungal infections. *Curr Opin Infect Dis* 2013;26(3):270–276
3. Rosen PP. Specific infections. Rosen's breast pathology, 2nd edn. New York: Lippincott Williams & Wilkins; 2001. p. 65-66.
4. Motamedshariati M. Fungal colonization within a tissue expander: a case report. *Ann Plast Surg* 2012 Feb;68(2):150–152.
5. Anaissie EJ, Stratton SL, Dignani MC, et al. Pathogenic Aspergillus species recovered from a hospital water system: a 3-year prospective study. *Clin Infect Dis* 2002 Mar 15; 34 (6):780–789.
6. Klost SP, Ludwig K, Kreuter M, Diallo R, Heindel W. Aspergilloma of the breast in a woman with acute myeloid leukemia. *Am J Roentgenol* 2002;178:1236-1238.
7. Nasit JG, Sojitra N, Bhalra R, Dhruva G. Aspergillosis of bilateral breast and chest wall in an immunocompetent male masquerading as breast cancer. *Int J Health Allied Sci* 2013;2:212–215.
8. Risha A, André R, Smeets A, Christiaens MR. Aspergilloma of the breast in a lung transplantation patient: a case report. *Acta Chir Belg* 2006 Nov- Dec;106(6):730–731.

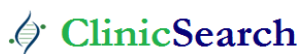9. Sukhamwang N, Chaiwun B, Trakultivakorn H. Fungal infection of the breast: Two reported cases diagnosed by fine needle aspiration (FNA) cytology. *Chiang Mai Med J* 2009; 48: 65–70.
10. Stevens DA. Diagnosis of fungal infections: current status. *J Antimicrob Chemother* 2002 Feb;49 Suppl1:11–19.
11. Alastruey-Izquierdo A, Mellado E, Pelaez T, Peman J, Zapico S, Alvarez M, et al. Population-based survey of filamentous fungi and antifungal resistance in Spain (FILPOP Study). *Antimicrob Agents Chemother*. 2013;57(7):3380–3387.
12. Nakashima K, Yamada N, Yoshida Y, Yamamoto O. Primary Cutaneous Aspergillosis. *Acta Derm Venereol* 2010;90:519-520.
13. Zeeshan S, Mahmood SF, Sattar AK. Aspergillus as a rare cause of non-healing traumatic breast wound. *Int J Case Rep Imag* 2016;7(4):235–239
14. Stevens DA. Diagnosis of fungal infections: current status. *J Antimicrob Chemother* 2002 Feb;49 Suppl1:11–19.
15. Betal D, Macneill FA. Chronic breast abscess due to *Mycobacterium fortuitum*: a case report. *J Med Case Rep* 2011 May 18; 5: 188.

**Ready to submit your research? Choose ClinicSearch and benefit from:**

- fast, convenient online submission
- rigorous peer review by experienced research in your field
- rapid publication on acceptance
- authors retain copyrights
- unique DOI for all articles
- immediate, unrestricted online access

**At ClinicSearch, research is always in progress.**

Learn more <https://clinicsearchonline.org/journals/carcinogenesis-and-chemotherapy>



© The Author(s) 2022. **Open Access** This article is licensed under a Creative Commons Attribution 4.0 International License, which permits use, sharing, adaptation, distribution and reproduction in any medium or format, as long as you give appropriate credit to the original author(s) and the source, provide a link to the Creative Commons licence, and indicate if changes were made. The images or other third party material in this article are included in the article's Creative Commons licence, unless indicated otherwise in a credit line to the material. If material is not included in the article's Creative Commons licence and your intended use is not permitted by statutory regulation or exceeds the permitted use, you will need to obtain permission directly from the copyright holder. To view a copy of this licence, visit <http://creativecommons.org/licenses/by/4.0/>. The Creative Commons Public Domain Dedication waiver (<http://creativecommons.org/publicdomain/zero/1.0/>) applies to the data made available in this article, unless otherwise stated in a credit line to the data.