

# Orthodontic Extrusion with Crown Restoration in The Management of Anterior Teeth Crown-Root Fracture: A Case Report

Wang Jing, Huo Na, Cai Chuan, Xu Lulu\*

Department of Stomatology, The First Medical Center of PLA General Hospital, 28 Fuxing Road, Haidian District, Beijing, China

\*Corresponding Author: Xu Lulu, Department of Stomatology, The First Medical Center of PLA General Hospital, 28 Fuxing Road, Haidian District, Beijing, China.

Received date: March 27, 2023; Accepted date: April 07, 2023; Published date: April 18, 2023

**Citation:** Wang Jing, Huo Na, Cai Chuan, Xu Lulu (2023). Orthodontic Extrusion with crown restoration in the management of anterior teeth crown-root fracture: *Journal of Clinical Anatomy*, 2(2) DOI:10.31579/2834-5134/018

**Copyright:** © 2023 Xu Lulu, This is an open access article distributed under the Creative Commons Attribution License, which permits unrestricted use, distribution, and reproduction in any medium, provided the original work is properly cited.

## Abstract

Crown-root fracture is a rare type of dental traumatic injury. Management of traumatized teeth sometimes requires a multidisciplinary approach to obtain better esthetic results as well as for the conservation of tooth structure. This article describes the management of a case of oblique crown root fracture of anterior teeth. After the removal of the coronal fragment, the roots were filled with calcium hydroxide. Orthodontic extrusion was initiated for 4 months, and 3 mm extrusion was achieved. The ceramic crown was cemented on anterior fracture teeth. The periodontal condition appeared to be healthy and good esthetic was maintained during the follow-up appointment.

**Keywords:** Fracture; Orthodontic extrusion; Anterior teeth; Ceramic crown

## Introduction

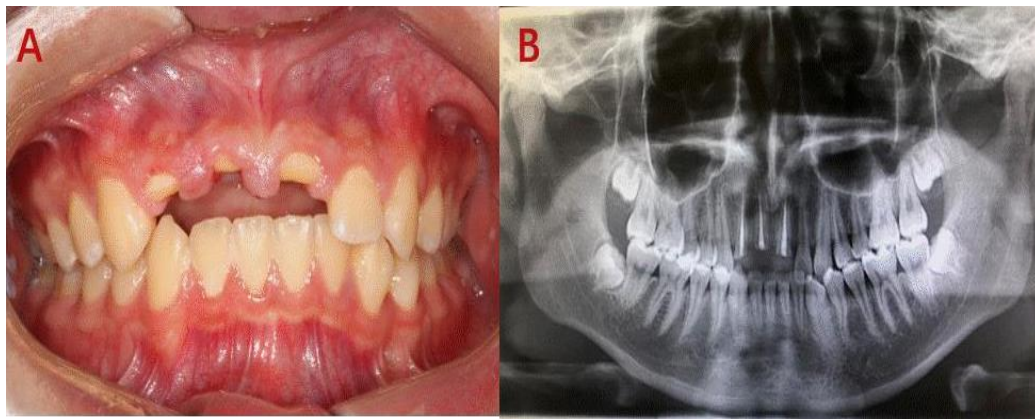
Crown-root fracture is a rare type of dental traumatic injury, affecting 0.5% to 7% of permanent teeth<sup>1</sup>. In this type of injury, the wound involves damage to the pulp, cementum, dentin, and periodontal ligament. Depending on the severity of the injury, multiple or single fractures of the root can be observed. Management of traumatized teeth sometimes requires a multidisciplinary approach to obtain better esthetic results as well as for the conservation of tooth structure<sup>2</sup>. Exposure of the fractured margin into the oral cavity is desirable. This may be achieved by 3: (i) crown lengthening, (ii) surgical extrusion, and (iii) orthodontic extrusion. This case report presents the management of a cervical root fracture using orthodontic extrusion and final restoration with a ceramic crown.

## Case report

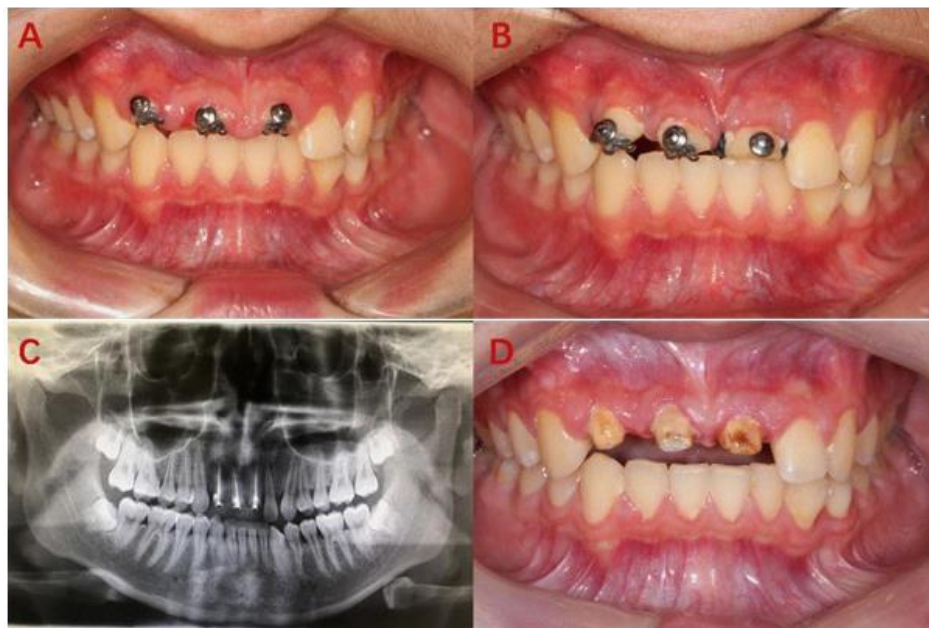
A 22-year-old man reported to the Department of Orthodontic Dentistry with a complaint of damaged anterior teeth. History revealed that the patient had an injury to the front tooth region 1 month ago, due to a fall. Intraoral examination revealed anterior teeth crown-root fractured, the coronal fragment was extracted (Fig1A). The fracture line was located subgingivally

on the mesiobuccal and mesiolingual aspects. The periapical radiograph revealed that the fracture line was extending up to the level of the alveolar crest. The root canal treatment of fractured teeth was finished (Fig1B).

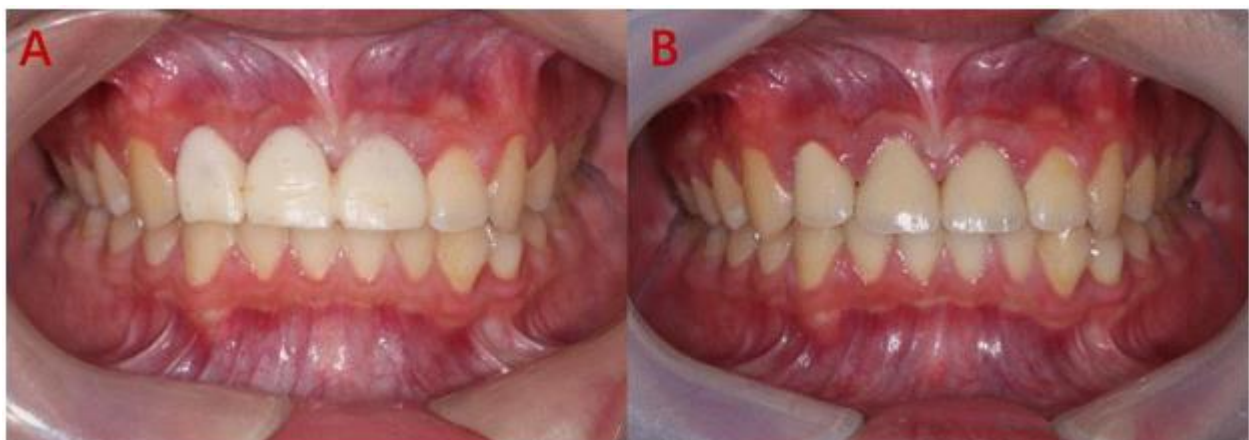Since the fracture line extended up to the alveolar bone crest, it was possible to initiate extrusion of the root so as to facilitate placement of coronal restoration and long-term attachment health. So orthodontic extrusion was possible. The lingual button was bonded on the fracture side of the anterior teeth (Fig2A). The patient was revisioned once a month and orthodontic traction was taken. Removable appliances were used for the lower arch to tract anterior teeth with the help of the buttons. A small amount of both labial and palatal mucous recontouring was done using the electrotome method to allow for proper finishing of the crown margins (Fig2B). Interactive traction was used for 4 months, and 3 mm extrusion was achieved (Fig2C D). The temporary crown was used for 6 months (Fig). Finally, the ceramic crown was cemented on 12 11, and 21 (Fig3B). During the three-month follow-up appointment, the periodontium appeared to be healthy and a good esthetic was maintained.



**Figure 1 A :** Intraoral examination revealed anterior teeth crown-root fractured, and the coronal fragment was extracted ; **B :** Periapical radiograph revealed that the fracture line was extending up to the level of the alveolar crest. The root canal treatment of fractured teeth was finished



**Figure 2 A :** Lingual button was bonded on the fracture side of the anterior teeth ; **B :** A small amount of both labial and palatal mucosal recontouring was done using the electrosurgical method to allow for proper finishing of the crown margins ; **C D :** Interactive traction was used for 4 months, and 3 mm extrusion was achieved



**Figure 3 A :** The temporary crown was used for 6 months ; **B :** the ceramic crown was cemented on 12 11 and 21

## Discussion

The orthodontic forced eruption was first described by Heithersay as coronal orthodontic movement achieved by applying continuous orthodontic force for the purpose of preserving soft tissues and gaining vertical bone height. Orthodontic extrusion is a safe, minimally invasive, and highly predictable treatment. It shows several advantages if compared to surgical crown lengthening<sup>4</sup>. First, tooth structure and periodontal support maintenance is crucial. As previously mentioned, it is required to extend bone resection on the adjacent teeth to harmonize the gingival morphology in surgical crown lengthening. This causes bone loss and possible damage of the periodontal support as well as a worsening of the crown/root ratio of these teeth. Conversely, orthodontic extrusion can just cause tooth displacement or even increase the volume of dental support tissues, which is particularly advantageous for implant purposes<sup>5</sup>.

Orthodontic extrusion can be obtained using different orthodontic strategies<sup>6</sup>: fixed appliances, removable appliances, and temporary anchorage devices such as mini-screw. Different treatment choice variables must be considered, such as patient preference, oral hygiene, availability of an appropriate orthodontic anchorage, and amount of dental crown available. As a general rule, the less periodontal support, the less force needed for extrusion. An accelerated movement rate may result in a risk of tissue damage and ankylosis. A sufficient crown-root ratio (ideally less than 1:1), healthy gingiva, and osseous structures without any pathological signs are required for successful extrusion and favorable esthetic outcomes in crown-root fractured teeth. The current knowledge suggests the application of light and constant forces of 15 g for the anterior teeth and 50 g for posterior teeth are optimal to extrude a tooth for implant site enhancement<sup>7</sup>.

After the successful application of orthodontic extrusion, the stabilization phase takes place. The resin crown was used as a temporary crown for 6 months. This phase is important to allow for proper reorganization of the soft tissue and remodeling of the bone in the so-called "osteoid formation" phase, thus discouraging relapse.

It is preferable to choose orthodontic extrusion if a highly predictable treatment is requested if an orthodontic device is already present, and if it is necessary to preserve tooth vitality or treat teeth non-compatible with an atraumatic extraction. Orthodontic movements, especially if performed on traumatized teeth or through the application of heavy forces, can cause root resorption<sup>8</sup>. However, it can be considered a rare event when performing extrusive movement. Moreover, there was no correlation between the degree of extrusion and the occurrence of root resorption.

## Conclusion

Using a combination of orthodontic extrusion and crown restoration may be considered for the treatment of crown root fractures because:

1. Esthetics is maintained until the final restoration placement by highly

cost-effective.

2. Excellent esthetics and periodontal health is maintained if the final restoration is made after orthodontic extrusion.
3. It is a simple and safe method and hence more acceptable to the patient.
4. The prospects of this treatment modality for crown root fractures of posterior teeth need to be investigated.
5. Supported by National key research and development program 2022YFC3103202; Military medical science Foundation of Youth project 21QNPY104; National natural science foundation 8217086

## References

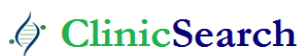1. Cordaro, M., Staderini, E., Torsello, F., Grande, N. M., Turchi, M., & Cordaro, M. (2021). Orthodontic extrusion vs. surgical extrusion to rehabilitate severely damaged teeth: a literature review. *International Journal of Environmental Research and Public Health*, 18(18), 9530.
2. Alsahhaf, A., & Att, W. (2016). Orthodontic extrusion for pre-implant site enhancement: Principles and clinical guidelines. *Journal of prosthodontic research*, 60(3), 145-155.
3. Zasciurinskiene, E., Lindsten, R., Slotte, C., & Bjerklin, K. (2016). Orthodontic treatment in periodontitis-susceptible subjects: a systematic literature review. *Clinical and experimental dental research*, 2(2), 162-173.
4. Canoglu, H., Gungor, H. C., & Cehreli, Z. C. (2007). Management of cervical root fracture using orthodontic extrusion and crown reattachment: a case report. *Oral Surgery, Oral Medicine, Oral Pathology, Oral Radiology, and Endodontology*, 104(3), e46-e49.
5. Elisabeth Reichardt, Ralf Krug, Michael M. Bornstein, Jürgen Tomasch, Carlalberta Verna, Gabriel Krastl. Orthodontic Forced Eruption of Permanent Anterior Teeth with Subgingival Fractures: A Systematic Review. *Int J Environ Res Public Health*. 2021, 18, 12580.
6. Huang, G., Yang, M., Qali, M., Wang, T. J., Li, C., & Chang, Y. C. (2021). Clinical considerations in orthodontically forced eruption for restorative purposes. *Journal of clinical medicine*, 10(24), 5950.
7. Isola, G., Nucera, R., Damonte, S., Ugolini, A., De Mari, A., & Migliorati, M. (2022). Implant Site Changes in Three Different Clinical Approaches: Orthodontic Extrusion, Regenerative Surgery and Spontaneous Healing after Extraction: A Systematic Review. *Journal of Clinical Medicine*, 11(21), 6347.
8. Suprabha, B. S., Kundabala, M., Subraya, M., & Kancherla, P. (2006). Reattachment and orthodontic extrusion in the management of an incisor crown-root fracture: a case report. *J Clin Pediatr Dent*, 30(3), 211-214.

**Ready to submit your research? Choose ClinicSearch and benefit from:**

- fast, convenient online submission
- rigorous peer review by experienced research in your field
- rapid publication on acceptance
- authors retain copyrights
- unique DOI for all articles
- immediate, unrestricted online access

**At ClinicSearch, research is always in progress.**

Learn more <http://clinicsearchonline.org/journals/journal-of-clinical-anatomy>



© The Author(s) 2022. **Open Access** This article is licensed under a Creative Commons Attribution 4.0 International License, which permits use, sharing, adaptation, distribution and reproduction in any medium or format, as long as you give appropriate credit to the original author(s) and the source, provide a link to the Creative Commons licence, and indicate if changes were made. The images or other third party material in this article are included in the article's Creative Commons licence, unless indicated otherwise in a credit line to the material. If material is not included in the article's Creative Commons licence and your intended use is not permitted by statutory regulation or exceeds the permitted use, you will need to obtain permission directly from the copyright holder. To view a copy of this licence, visit <http://creativecommons.org/licenses/by/4.0/>. The Creative Commons Public Domain Dedication waiver (<http://creativecommons.org/publicdomain/zero/1.0/>) applies to the data made available in this article, unless otherwise stated in a credit line to the data.