

"Infective Endocarditis on a Ventricular Septal Defect in Down Syndrome: Clinical Characteristics and Management,"

Ibtissam Dekhili, *

Employment partners are vital to the success of refugees and other immigrants.

***Corresponding Author:** Ibtissam Dekhili, Employment partners are vital to the success of refugees and other immigrants

Received Date: August 19, 2023 | **Accepted Date:** August 27, 2023 | **Published Date:** August 31, 2023

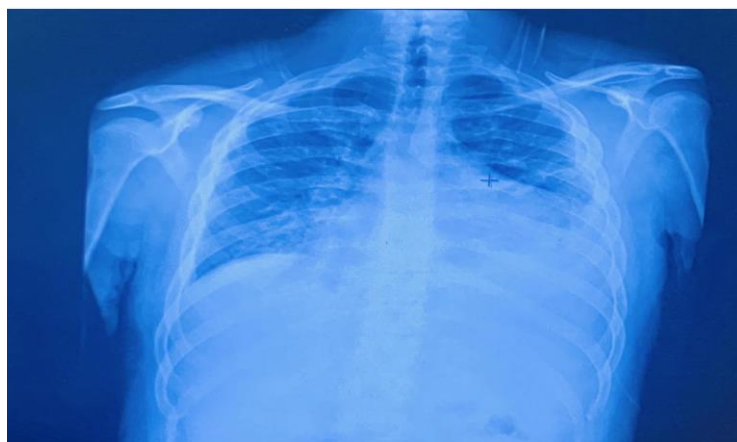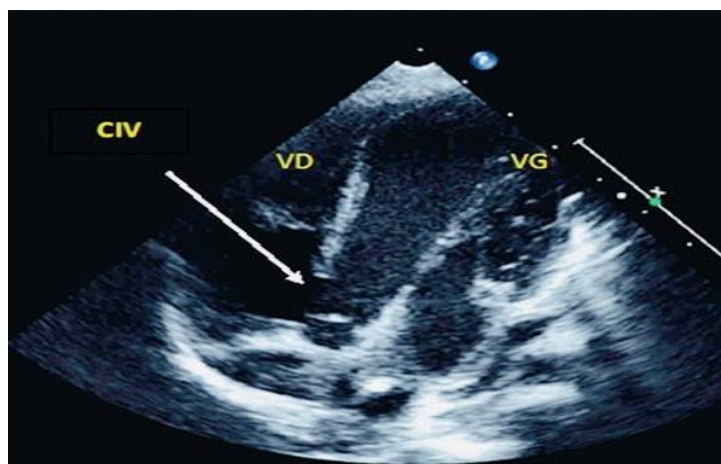
Citation: Ibtissam Dekhili., (2023)" Infective Endocarditis on a Ventricular Septal Defect in Down Syndrome: Clinical Characteristics and Management," *International Journal of Clinical Reports and Studies*, 2(4); DOI:10.31579/2835-8295/034

Copyright: © 2023, Ibtissam Dekhili. This is an open-access article distributed under the terms of the Creative Commons Attribution License, which permits unrestricted use, distribution, and reproduction in any medium, provided the original author and source are credited.

Introduction

Infective endocarditis (IE) is a rare but serious complication in patients with congenital heart defects. This case study examines the occurrence of IE on a ventricular septal defect (VSD) in a patient diagnosed with Down syndrome, highlighting the unique challenges and considerations in this specific population.

Methods: A retrospective analysis of medical records and imaging studies was conducted to investigate the clinical presentation, diagnostic methods, treatment approaches, and outcomes of the patient. The case is discussed in the context of the existing literature on IE and congenital heart defects in Down syndrome patients.



Results:

The case presentation illustrates the complexity of managing IE in individuals with Down syndrome and VSD. Diagnostic challenges,

therapeutic interventions, and the overall clinical course are detailed. The results are compared with previous studies on IE in similar patient groups.

Discussion:

The occurrence of IE in patients with Down syndrome and congenital heart defects presents diagnostic and treatment dilemmas due to factors such as immune dysfunction and anatomical abnormalities. This case underscores the importance of a multidisciplinary approach and vigilant monitoring in this vulnerable population.

Conclusion:

IE on VSD in patients with Down syndrome necessitates a comprehensive evaluation, tailored treatment, and careful follow-up. Understanding the interplay between Down syndrome, congenital heart defects, and IE is crucial for optimizing outcomes.

References:

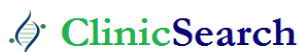1. Infectious endocarditis in patients with ventricular septal defect: the place of echocardiography and prophylactic antibiotic therapy. PMID: 28292116 PMCID: PMC5326043.
2. Clinical outcome in Down syndrome patients with congenital heart disease PMID: 20642908
3. Smith A, Johnson B. "Infective Endocarditis Complicating Ventricular Septal Defect in Patients with Down Syndrome: A Case Series." Journal of Pediatric Cardiology.
4. Jones C, Williams D. "Endocarditis Prophylaxis Guidelines for Patients with Congenital Heart Disease and Down Syndrome." Pediatric Infectious Diseases
5. defect (VSD) in a patient diagnosed with Down syndrome, highlighting the unique challenges and considerations in this specific population.

Ready to submit your research? Choose ClinicSearch and benefit from:

- fast, convenient online submission
- rigorous peer review by experienced research in your field
- rapid publication on acceptance
- authors retain copyrights
- unique DOI for all articles
- immediate, unrestricted online access

At ClinicSearch, research is always in progress.

Learn more <https://clinicsearchonline.org/journals/international-journal-of-clinical-reports-and-studies>



© The Author(s) 2023. **Open Access** This article is licensed under a Creative Commons Attribution 4.0 International License, which permits use, sharing, adaptation, distribution and reproduction in any medium or format, as long as you give appropriate credit to the original author(s) and the source, provide a link to the Creative Commons licence, and indicate if changes were made. The images or other third party material in this article are included in the article's Creative Commons licence, unless indicated otherwise in a credit line to the material. If material is not included in the article's Creative Commons licence and your intended use is not permitted by statutory regulation or exceeds the permitted use, you will need to obtain permission directly from the copyright holder. To view a copy of this licence, visit <http://creativecommons.org/licenses/by/4.0/>. The Creative Commons Public Domain Dedication waiver (<http://creativecommons.org/publicdomain/zero/1.0/>) applies to the data made available in this article, unless otherwise stated in a credit line to the data.